Endoscopic and surgical management of pancreato-mediastinal collections secondary to pancreatic duct disruption in acute and chronic pancreatitis: experience from a specialist pancreatitis MDT

James Chambers[1], S Saikia[1], J Leeds[1], M Nayar[1], D Campbell[2], E O'Connor[2], S Pandanaboyana[1]
[1] Newcastle upon Tyne Hospitals NHS Foundation Trust [2] Great North Children's Hospital

The Newcastle upon Tyne Hospitals NHS Foundation Trust

KEY MESSAGE: All six confirmed pancreato-mediastinal collections demonstrated duct disruption and required MDT-directed intervention.

Figure 1. MRCP demonstrating a large pancreato-mediastinal collection.

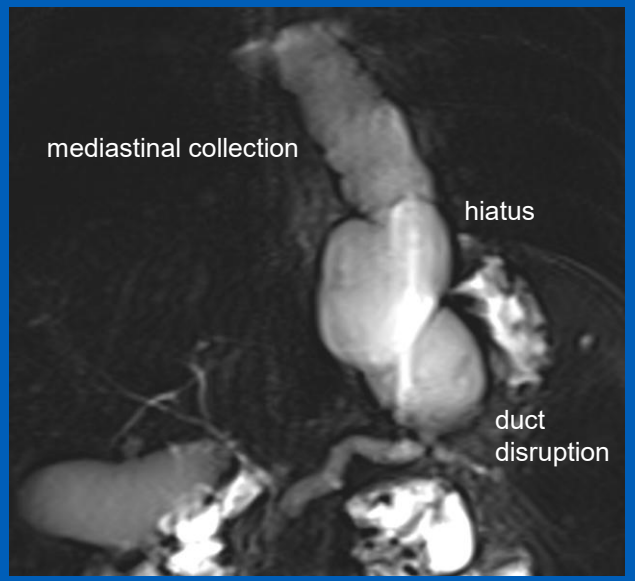

METHODS

- Radiology DB + MDT referrals
- 7 episodes,1 excluded (haematoma)
- 6 episodes in 5 patients

COHORT

- 80% paediatric, 60% PRSS1-related
- 80% features of CP

Figure 2. Endoscopic cystogastrostomy stent placement.

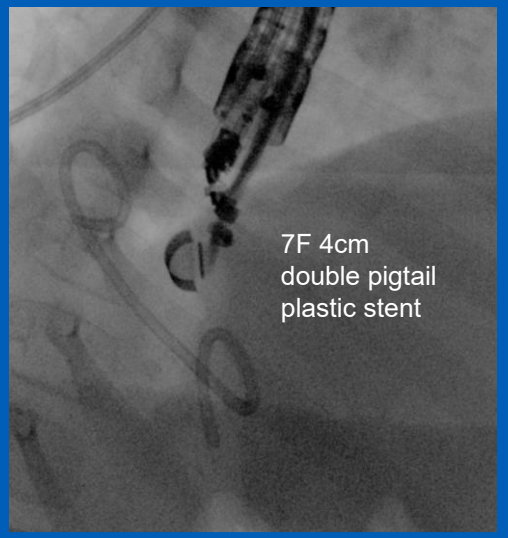

MANAGEMENT

- TPN and Octreotide used in 80%
- Intervention performed in 100%
- Endoscopic: EUS cystogastrostomy, EUS aspiration, ERCP PD stenting
- Surgical: lap cystogastrostomy, total pancreatectomy, TPIAT

Figure 3. MRCP showing resolution.



CONCLUSIONS

- Rare manifestation of duct disruption
- Predominantly paediatric cohort
- Specialist MDT review is central to care
- Limitation – can't account for non-referrals

Chong E, *et al*. Endoscopic transmural drainage is associated with improved outcomes in disconnected pancreatic duct syndrome: a systematic review and meta-analysis. BMC Gastroenterol. 2021 Feb 25;21(1):87.