UKIEUS & PSGBI ANNUAL SCIENTIFIC MEETING 2026 · POSTER

Bile cytology at percutaneous biliary drainage in suspected malignant biliary obstruction: diagnostic yield and contribution to management decisions

Kamran Dar[1], Durgesh Rana[2], Charlotte Ebenezer[2], Nadira Narine[2], Zahid Khan[3], Asma Sultana[1]
[1]Department of HPB Surgery · [2]Department of Pathology · [3]Department of Interventional Radiology
Royal Blackburn Hospital, East Lancashire Teaching Hospitals NHS Trust, United Kingdom

84.4%
diagnostic yield from bile
27 of 32 malignant or suspicious

89.7%
sensitivity, no false positives
26 of 29 confirmed cases

6 of 8
resections on bile cytology alone
no other positive morphology before surgery

1
procedure to diagnosis and treatment
in 6 patients (18.8%)

THE OPPORTUNITY

1. **ERCP fails**
   21 of 32 patients (65.6%) before drainage
2. **PTBD ± brushings performed**
   drainage is needed regardless
3. **Bile aspirated — usually discarded**
   a specimen already in hand, at no extra risk
4. **Sent for cytology**
   aim: diagnostic yield, prior burden, treatment supported

METHODS

- Prospective single-centre study, June 2025 – August 2026
- Consecutive PTBD for suspected malignant biliary obstruction; **new diagnoses only**
- Specialist cytopathologist; five categories, N1 unsatisfactory to N5 malignant
- Procedures counted from first imaging suspicious for malignancy
- Reference standard: histology, else MDT consensus with follow-up

STUDY FLOW

PTBD with bile sent for cytology	37
Metastasis from known primary	−3
Recurrence after previous resection	−1
Diagnosed elsewhere beforehand	−1
Analysed — new diagnoses	**32**

COHORT

32 patients	**20:12** male : female	**72** median age (54–91)

LEVEL OF OBSTRUCTION

Distal common bile duct	25
Liver hilum	5
Proximal common bile duct	2

UNDERLYING LESION

Mass	22
Stricture	5
Radiologically occult	5

CYTOLOGY RESULT

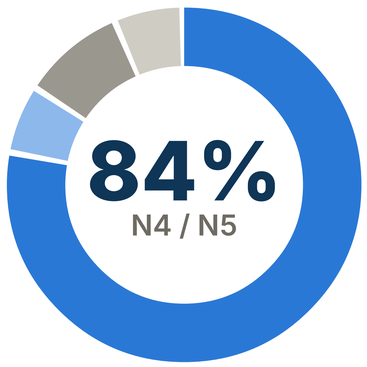

N5 malignant	25
N4 suspicious	2
N2 negative	3
N1 unsatisfactory	2

Yield	**84.4%** (95% CI 68.2–93.1)
Sensitivity	**89.7%** (95% CI 73.6–96.4)
False positives	**0**
Confirmed by histology / MDT	**16 / 15** (1 died first)

DIAGNOSTIC BURDEN

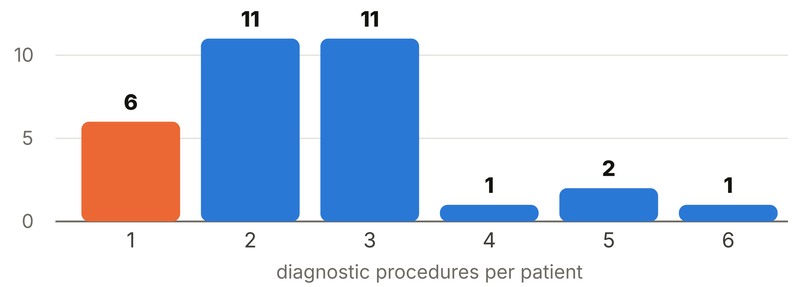

81 procedures in 32 patients (median 2, range 1–6). **Orange**: diagnosed and treated after a single procedure.

DEFINITIVE MANAGEMENT

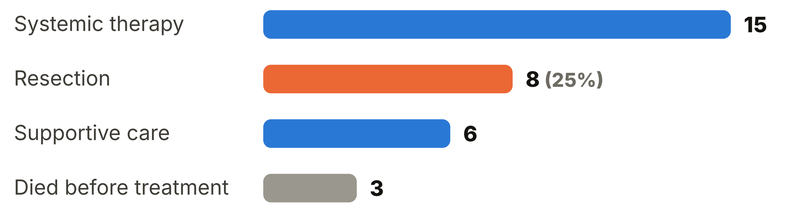

6 of 8
resections proceeded with bile cytology as the only positive morphological diagnosis
Major pancreatic and biliary surgery, on a specimen that would otherwise have been thrown away.

CONCLUSIONS

- Bile from PTBD gives a diagnosis in most patients, **at no added procedural risk**
- Sufficient to proceed to resection in 6 of 8 operated patients
- **Send the bile:** routine cytology at every PTBD

LIMITATIONS

Single centre; specialist reporting required; reference standard incorporated cytology in MDT-confirmed patients. Specificity not calculable — the only confirmed benign case gave an unsatisfactory sample.

Correspondence: **kamranhassan999@gmail.com**